



# Contemporary views on female pelvic anatomy

MATTHEW D. BARBER, MD, MHS

**T**he durable surgical repair of pelvic organ prolapse and its related disorders remains a significant challenge. The pelvic reconstructive surgeon needs an intimate knowledge of relevant surgical landmarks as well as a fundamental understanding of the biomechanics of pelvic organ support in order to successfully restore normal visceral anatomy and function. Rather than presenting a detailed description of female pelvic anatomy, this review provides a discussion of the contemporary understanding of female pelvic organ support, with emphasis on the functional and surgical anatomy of the vagina, urethra, and pelvic floor, as well as a discussion of obturator anatomy, as several new innovative procedures now use the transobturator approach.

## ■ ORIENTATION OF THE BONY PELVIS

The pelvic bones are the ilium, ischium, pubic rami, sacrum, and coccyx. The bony pelvis is the rigid foundation to which all of the pelvic structures are ultimately anchored. Although pelvic surgeons often visualize the orientation of the pelvis in the supine or lithotomy position, it is important to understand and discuss the bony pelvis from the perspective of a standing woman. In the standing woman, the pelvis is oriented such that the anterior superior iliac spine and the front edge of the pubic symphysis are in the same vertical plane, perpendicular to the floor (**Figure 1**). As a consequence, the pelvic inlet is tilted anteriorly and the ischiopubic rami and genital hiatus are parallel to the ground. In the upright posi-

tion, the bony arches of the pelvic inlet are oriented in an almost vertical plane. This directs the pressure of the intra-abdominal and pelvic contents toward the bones of the pelvis instead of the muscles and endopelvic fascia attachments of the pelvic floor. Thus, in the standing position, the bony pelvis is oriented such that forces are dispersed to minimize the pressures on the pelvic viscera and musculature and will transmit the forces to the bones that are better suited to the long-term, cumulative stress of daily life. Where the pubic rami articulate in the midline, they are nearly horizontal. Much of the weight of the abdominal and pelvic viscera is supported by the bony articulation inferiorly.

## Varied shape, orientation associated with prolapse

Variations in the orientation and shape of the bony pelvis have been associated with the development of pelvic organ prolapse. Specifically, a loss of lumbar lordosis and a pelvic inlet that is less vertically oriented is more common in women who develop genital prolapse than in those who do not.<sup>1,2</sup> A less vertical orientation of the pelvic inlet is thought to result in an alteration of the intra-abdominal vector forces that are normally directed anteriorly to the pubic symphysis such that a greater proportion is directed toward the pelvic viscera and their connective tissue and muscular supports. Similarly, women with a wide transverse pelvic inlet appear to be at increased risk of developing pelvic organ prolapse.<sup>3,4</sup> Some have theorized that a wider pelvic inlet provides a larger hiatus for abdominal pressure transmission to the pelvic floor, which leads to loss of pelvic visceral support over time.<sup>3</sup> Variations in the shape and orientation of the bony pelvis are also an important factor that influences maternal soft-tissue damage and nerve injury during parturition.

## ■ PELVIC FLOOR MUSCULATURE

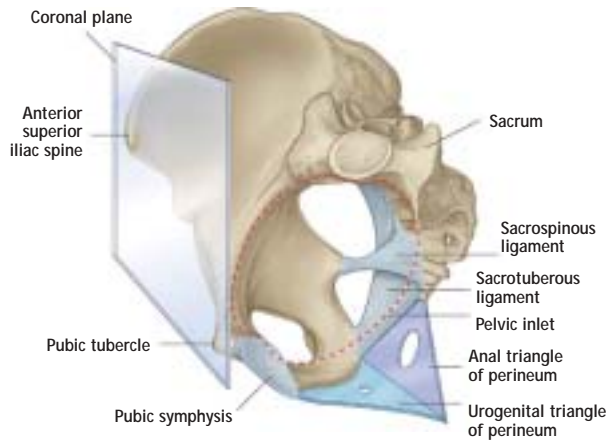
The skeletal muscles of the pelvic floor include the levator ani muscles, the coccygeus, the external anal sphincter, the striated urethral sphincter, and the deep and superficial perineal muscles. The muscles of

---

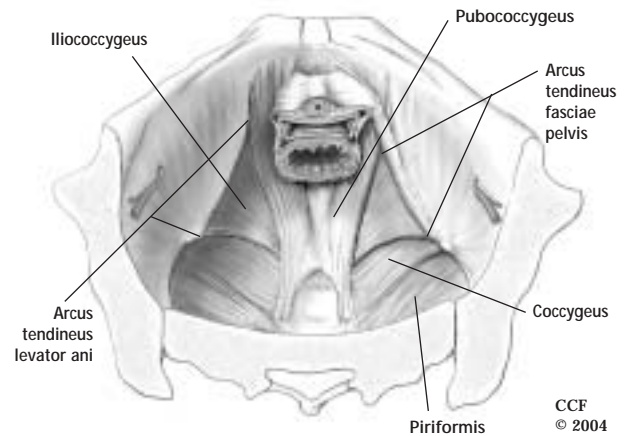
From the Section of Urogynecology and Reconstructive Pelvic Surgery, Department of Obstetrics and Gynecology, The Cleveland Clinic Foundation, Cleveland, OH.

**Address:** Matthew D. Barber, MD, MHS, Director of Clinical Research, Section of Urogynecology and Reconstructive Pelvic Surgery, Department of Obstetrics and Gynecology, The Cleveland Clinic Foundation, 9500 Euclid Avenue, A81, Cleveland, OH 44195; barberm2@ccf.org.

**Disclosure:** Dr. Barber reported that he has no financial interests or affiliations that pose a potential conflict of interest with this article.



**FIGURE 1.** Orientation of the bony pelvis in the standing position. In this position, the anterior superior iliac spine and the pubic tubercle are perpendicular to the floor, whereas the urogenital triangle of the perineum is horizontal. Reprinted from Drake RL et al, eds, *Gray's Anatomy for Students*, copyright 2005, with permission from Elsevier.



**FIGURE 2.** Illustration of the female pelvic floor showing relationships of the muscles of the pelvic floor and sidewalls and their attachments from an abdominal view. The arcus tendineus fasciae pelvis has been removed on the left, showing the origins of the levator ani muscles. On the right, the arcus tendineus fasciae pelvis remains intact, showing the attachment of the lateral vagina via the endopelvic fascia (cutaway).

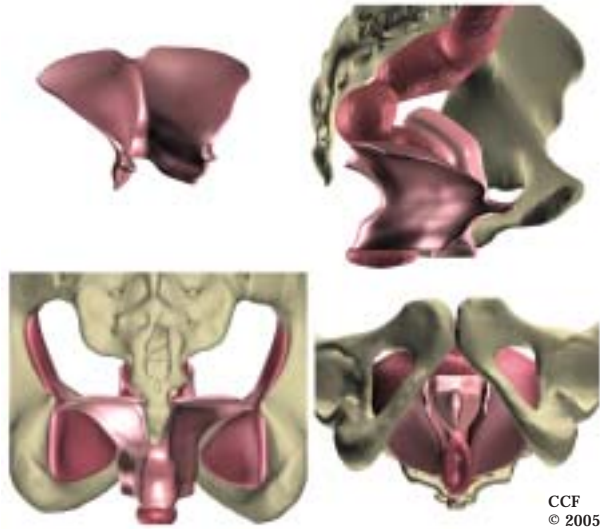
the pelvic floor, particularly the levator ani muscles, have a critical role in supporting the pelvic visceral organs and play an integral role in urinary, defecatory, and sexual function. The levator ani muscle complex consists of the pubococcygeus (also called pubovisceral), the puborectalis, and the iliococcygeus (**Figure 2**).<sup>5,6</sup> The pubococcygeus originates on the posterior inferior pubic rami and inserts on the midline-visceral organs and the anococcygeal raphe. The puborectalis also originates on the pubic bone, but its fibers pass posteriorly and form a sling around the vagina, rectum, and perineal body, resulting in the anorectal angle and promoting closure of the urogenital hiatus. The iliococcygeus originates from the arcus tendineus levator ani (ATLA), a linear thickening of the fascial covering of the obturator internus that runs from the ischial spine to the posterior surface of the ipsilateral superior pubic ramus. It inserts in the midline onto the anococcygeal raphe. The space between the levator ani musculature through which the urethra, vagina, and rectum pass is called the urogenital hiatus. The fusion of levator ani where they meet in the midline creates the so-called levator plate.

#### Constant resting tone, quick contraction ability

Pelvic floor muscles have a constant resting tone except during voiding, defecation, and the Valsalva maneuver. This activity serves to close the urethral and anal sphincters, narrow the urogenital hiatus, and provide a constant support for the pelvic viscera. The levator muscles and the skeletal components of the

urethral and anal sphincters all have the ability to contract quickly at the time of an acute stress, such as a cough or sneeze, in order to maintain continence and to relax during evacuation.

**Three-dimensional structure for levator ani complex**  
Although most anatomy and surgical texts depict the levator ani muscles as a bowl or funnel-shaped, this reflects the uncontracted state of the muscles as might be seen in a cadaver dissection and not that of a normally functioning levator. In a woman with normal pelvic floor function, the levator ani muscle complex in its tonically contracted state has an intricate three-dimensional structure in which its anterior portion (pubococcygeus and puborectalis) is oriented vertically as a sling around the mid-urethra, vagina, and anorectum and its posterior portion (the iliococcygeus) has a horizontal upwardly biconvex shape resembling a butterfly wing (**Figure 3**).<sup>7</sup> Thus, the anterior portion of the levator ani complex serves to close the urogenital hiatus and pull the urethra, vagina, perineum, and anorectum toward the pubic bone, whereas the horizontally oriented posterior portion (levator plate) serves as a supportive diaphragm or “backstop” behind the pelvic viscera. Loss of normal levator ani tone, through denervation or direct muscle trauma, results in laxity of the urogenital hiatus, loss of the horizontal orientation of the levator plate, and a more bowl-like configuration. These changes can be bilateral or asymmetric.<sup>8</sup>



**FIGURE 3.** Digitally enhanced three-dimensional reconstructions of the female pelvic floor from a magnetic resonance image of the pelvis in a normal nulliparous 23-year-old woman. Upper left: anterior view of the levator ani muscle with normal resting tone. Upper right: sagittal view of the levator ani muscle, bony pelvis, vagina, and rectum. Lower left: posterior view of the levator ani muscle, obturator internus muscles, and bony pelvis. Lower right: lithotomy view.

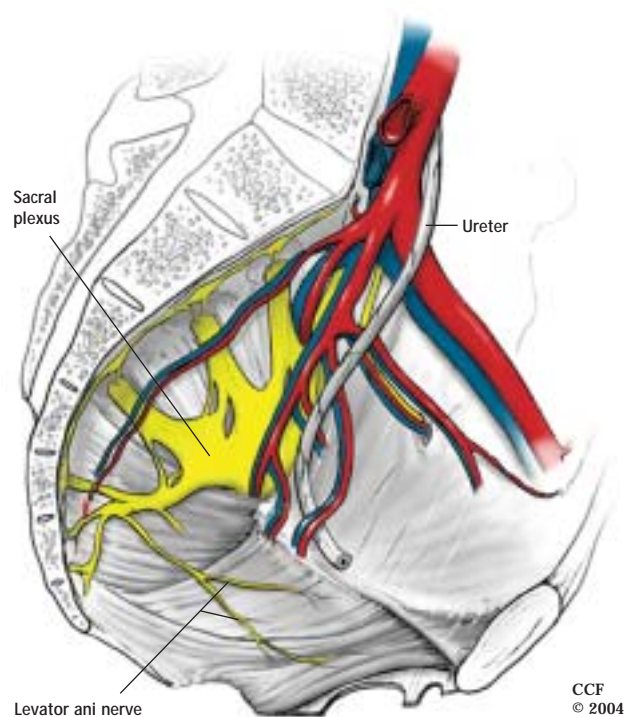
Such configurations are seen more often in women with pelvic organ prolapse than in those with normal pelvic organ support.<sup>7</sup>

#### ■ INNERVATION OF THE PELVIC FLOOR MUSCLES

The pudendal nerve innervates the striated urethral and anal sphincters as well as the deep and superficial perineal muscles and provides sensory innervation to the external genitalia. This nerve follows a complex course that originates from S2–S4 (with S3 providing the largest contribution) and travels behind the sacrospinous ligament just medial to the ischial spine, exiting the pelvis through the greater sciatic foramen. It then enters the ischiorectal fossa through the lesser sciatic foramen and travels through the pudendal canal (Alcock's canal) on the medial aspect of the obturator internus muscles before separating into several terminal branches that terminate within the muscles and skin of the perineum.

#### New insights into levator ani innervation

Many anatomic and surgical texts suggest that the levator ani muscles are dually innervated from (1) the pudendal nerve on the perineal surface and (2) direct branches of the sacral nerves on the pelvic surface. However, recent anatomic,<sup>9</sup> neurophysiologic,<sup>10,11</sup> and experimental evidence<sup>12–14</sup> indicates that these stan-



**FIGURE 4.** Sagittal view of the pelvis showing the arterial (red) and venous (blue) blood supply and nerves.

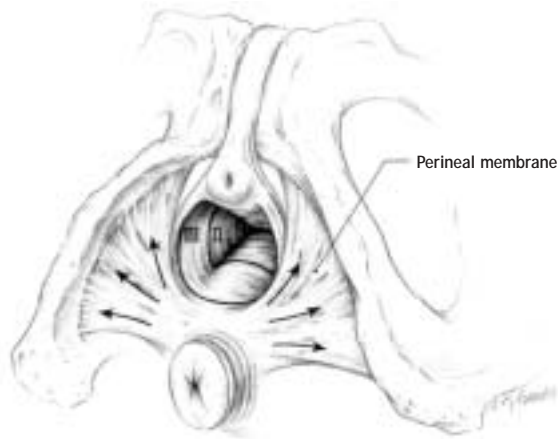
dard descriptions are inaccurate and that the levator ani muscles are innervated solely by a nerve traveling on the superior (intrapelvic) surface of the muscles without contribution of the pudendal nerve. This nerve, referred to as the levator ani nerve, originates from S3, S4, and/or S5 and innervates both the coccygeus and the levator ani muscle complex.<sup>9</sup> After exiting the sacral foramina, it travels 2 to 3 cm medial to the ischial spine and arcus tendineus levator ani across the coccygeus, iliococcygeus, pubococcygeus, and puborectalis (**Figure 4**). Occasionally, a separate nerve comes directly from S5 to innervate the puborectalis muscle independently.

Given its location, the levator ani nerve is susceptible to injury through parturition and pelvic surgery. Specifically, the fixation points used in the sacrospinous ligament fixation and the iliococcygeus vaginal vault suspensions are in close proximity to the course of the levator ani nerve. However, the impact that potential injury has on the long-term anatomic and functional success of these procedures is currently unknown.

#### ■ PERINEUM

Although the area between the vagina and anus is described clinically as the “perineum,” anatomical-



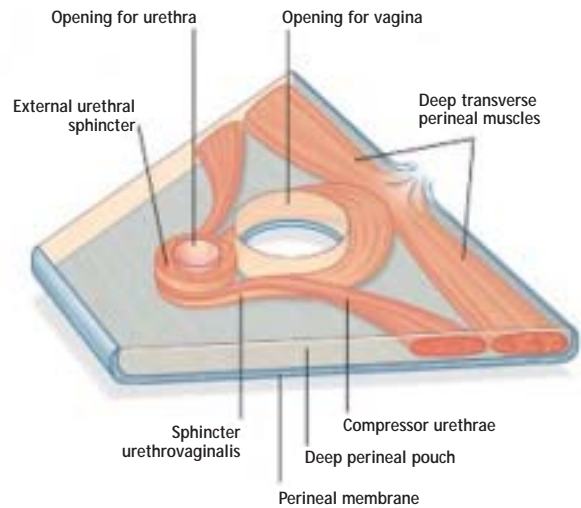


**FIGURE 5.** Perineal membrane with its attachments to the inferior pubic rami and direction of tension on fibers uniting through the perineal body (arrows). Reprinted from reference 16, copyright 1999, with permission from Elsevier.

ly the perineum is the entirety of the pelvic outlet inferior to the pelvic floor. The area between the vagina and anus is more aptly termed the *perineal body*. The borders of the female perineum are the ischiopubic rami, ischial tuberosities, sacrotuberous ligaments, and coccyx. A line connecting the ischial tuberosities divides the perineum into the urogenital triangle anteriorly and the anal triangle posteriorly. In the standing position, the urogenital triangle is oriented horizontally, whereas the anal triangle is tilted upward so that it faces more posteriorly (**Figure 1**).

The perineal membrane is a thick fibrous sheet that spans the urogenital triangle (**Figure 5**). It attaches laterally to the pubic arch and has a free posterior margin anchored in the midline by the perineal body. Although historically anatomists and clinicians have used the term *urogenital diaphragm* to describe this structure, this term has been abandoned because it erroneously implies a muscular diaphragm rather than a thick sheet of connective tissue.<sup>15,16</sup> The urethra and vagina penetrate through a hiatus in the perineal membrane (the urogenital hiatus) to exit at the vestibule. The perineal membrane, therefore, provides fixation of distal urethra, distal vagina, and perineal body to the pubic arches.

The urogenital triangle is divided into a superficial and deep perineal space by the perineal membrane. The superficial perineal space contains the superficial perineal muscles (ischiocavernosus, bulbospongiosus, superficial transverse perineal



**FIGURE 6.** Muscles of the deep perineal space. The perineal membrane is in the horizontal plane in the standing position. The muscles of the deep perineal space lie cephalad to the perineal membrane and below the levator ani muscles. Reprinted from Drake RL et al, eds, *Gray's Anatomy for Students*, copyright 2005, with permission from Elsevier.

muscles), the erectile tissue of the clitoris, the vestibular bulbs, and Bartholin's glands. The deep perineal space lies just deep to the perineal membrane and inferior to the levator ani muscles. Within this thin space lie the external urethral sphincter and the urethrovaginalis, compressor urethrae, and deep transverse perineal muscles (**Figure 6**).<sup>15,17</sup> The urethrovaginalis and compressor urethrae muscles provide accessory sphincter function to the urethra.<sup>17</sup> The urethrovaginalis muscle surrounds the distal urethra and vagina without passing between them and therefore acts as a sphincter to the vagina as well as to the distal urethra.<sup>15</sup> The deep transverse perineal muscle, along with its superficial counterpart, serves to stabilize the position of the perineal body and inferior border of the perineal membrane. There is some dispute as to whether the deep transverse perineal muscle is present in females, however.<sup>15</sup>

The perineal body marks the point of convergence of the bulbospongiosus muscle, superficial and deep transverse perinei, perineal membrane, external anal sphincter, posterior vaginal muscularis, and fibers from the puborectalis and pubococcygeus. The perineal body plays an important role in support of the distal vagina and in normal anorectal function. The vascular and nerve supply to the perineum, including the deep and superficial perineal spaces, is provided by the pudendal neurovascular bundle.

## ■ VAGINA

The vagina is a hollow, distensible, fibromuscular tube with rugal folds that extends from the vestibule to the uterine cervix. Its longitudinal shape resembles a trapezoid, as it is narrowest at the introitus and grows progressively wider as it approaches the vaginal apex and cervix. In the transverse dimension, the vagina is H-shaped at its distal end (toward the introitus) and flattened proximally. In the sagittal plane, the vagina has a distinct angulation so that its upper two thirds is directed toward the third and fourth sacral vertebrae and is almost horizontal in the standing position. In contrast, the lower third is nearly vertical as it passes through the perineal membrane to the vestibule. The angle between the upper and lower axes of the vagina is approximately 130°.<sup>18</sup>

### Three layers of vaginal wall

Histologically, the vaginal wall is composed of three layers: mucosa, muscularis, and adventitia.<sup>19,20</sup> The vaginal mucosa is the most superficial layer and consists of stratified squamous epithelium and a lamina propria. The vaginal muscularis is a well-developed fibromuscular layer consisting primarily of interdigitating smooth muscle bundles with smaller amounts of collagen, elastin, and vascular tissue.<sup>19,20</sup> The outermost adventitia is a variably discrete layer of collagen, elastin, and adipose tissue containing blood vessels, lymphatics, and nerves. The adventitia represents an extension of the visceral endopelvic fascia that surrounds the vagina and adjacent pelvic organs and allows for their independent expansion and contraction.

### No 'fascial' layer

Some have used the terms *pubocervical fascia* and *rectovaginal fascia* to describe the layer separating the vagina from the bladder and rectum, respectively. Although these terms are widely used, "fascia" is a misnomer in this context, as it does not accurately reflect the histology of the vagina. Numerous authors have performed histologic analysis of the vaginal wall and have failed to identify a distinct "fascial" layer.<sup>16,19,20</sup> Between the adjacent pelvic organs is primarily vaginal muscularis. The "fascia" often noted by pelvic surgeons during vaginal dissection refers, in fact, to layers that are developed as a result of separating the vaginal epithelium from the muscularis, or by splitting the vaginal muscularis layer.<sup>19</sup> The one area where there does appear to be dense connective tissue separating the vagina from an adjacent organ is the distal posterior vaginal wall. The connective tissue of the perineal body extends 2 to 4 cm cephalad

from the hymenal ring along the posterior vaginal wall between the smooth muscle layers of the vagina and the rectum.<sup>16</sup> This layer does not, however, extend the full length of the posterior vaginal wall.

## ■ SUPPORT OF THE VAGINA AND UTERUS

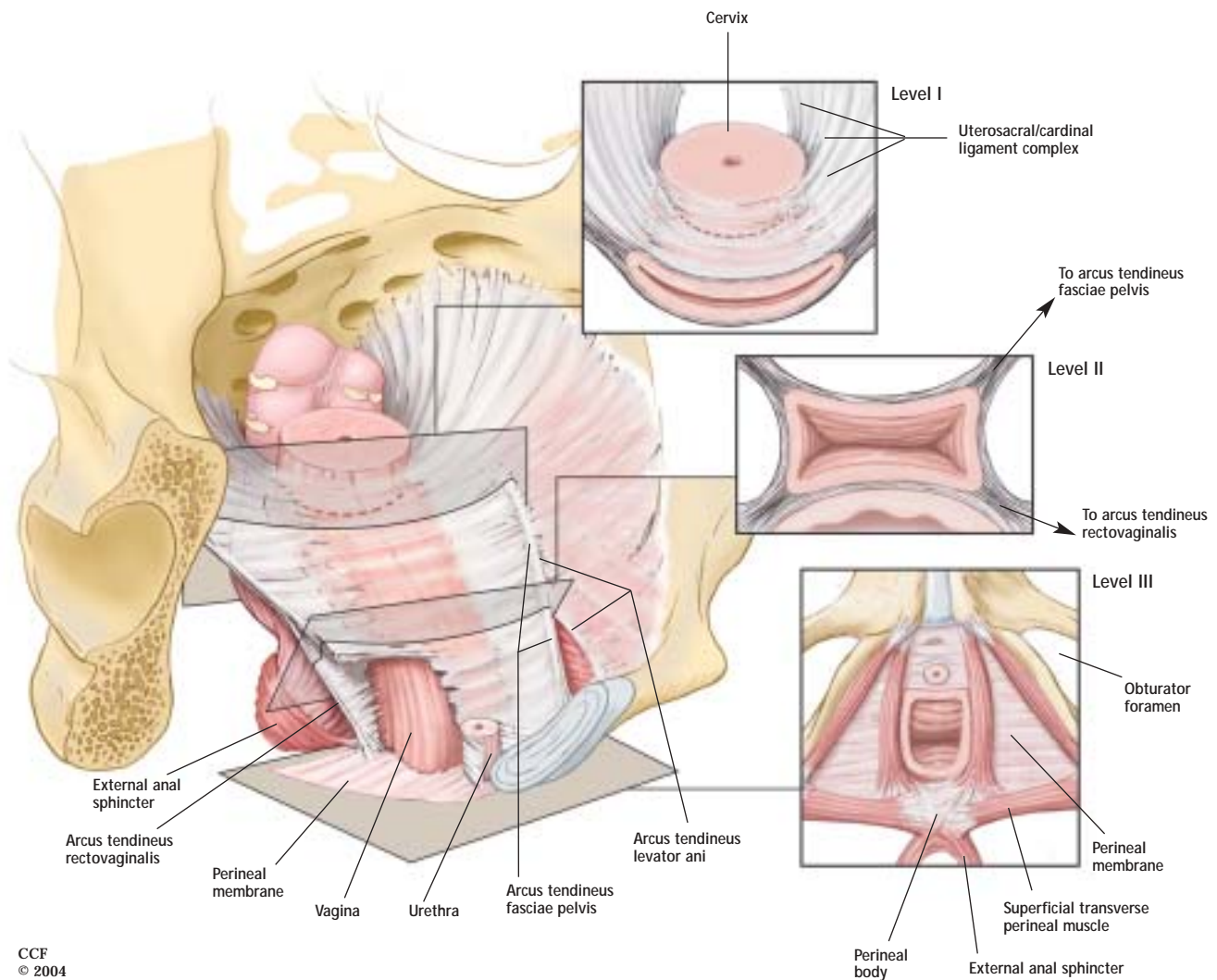
The normal axis of the pelvic organs in the standing woman places the upper two thirds of the vagina directly over the levator plate. The endopelvic fascia is the loose connective tissue network that envelops all of the organs of the pelvis and connects them loosely to the supportive musculature and bones of the pelvis. Histologically, it is composed of collagen, elastin, adipose tissue, nerves, vessels, lymph channels, and smooth muscle. This connective tissue network tethers the vagina and uterus in their normal anatomic location while allowing for the mobility of the viscera to permit storage of urine and stool, coitus, parturition, and defecation.

Several areas of the endopelvic fascia (and its associated peritoneum) have been named by anatomists. These are condensations of the endopelvic fascia and not true "ligaments": uterosacral ligament, cardinal ligament, broad ligament, mesovarium, mesosalpinx, and round ligament. The broad ligament, mesovarium, mesosalpinx, and round ligament do not play a role in support of the pelvic organs.

### Three integrated levels of support

DeLancey described the connective tissue supports of the vagina in three levels<sup>21</sup> (**Figure 7**). The uterosacral/cardinal ligament complex, which comprises level I support, is an intricate three-dimensional connective tissue structure that originates at the cervix and upper vagina and inserts at the pelvic sidewall and sacrum. Magnetic resonance images in healthy women reveal that the uterosacral ligament inserts in the area of the coccygeus and sacrospinous ligament in most women, with only 7% actually inserting into the sacrum.<sup>22</sup> The uterosacral/cardinal ligament complex suspends the uterus and upper vagina in its normal orientation. It serves to maintain vaginal length and keep the vaginal axis nearly horizontal in a standing woman so that it can be supported by the levator plate. Loss of level I support contributes to prolapse of the uterus and/or vaginal apex.

Contiguous with the uterosacral/cardinal ligament complex at the location of the ischial spine is level II support—the paravaginal attachments. The anterior vagina is suspended laterally to the arcus tendineus fasciae pelvis (ATFP), or white line, which is a thickened condensation of fascia overlying the iliococ-



**FIGURE 7.** Integrated levels of support: illustration of the normal vaginal axis and the three levels of support of the vagina and uterus from the perspective of a standing woman. In level I, the endopelvic fascia suspends the upper vagina and cervix from the lateral pelvic walls. Fibers of level I extend both vertically and posteriorly toward the sacrum. In level II, the vagina is attached to the arcus tendineus fasciae pelvis and superior fascia of the levator ani muscles. In level III, the distal vagina is supported by the perineal membrane and muscles. The insets show transverse sections made through the vagina perpendicular to the normal vaginal axis at each level.

cygeus. The ATFP originates on the ischial spine and inserts on the inferior aspect of the pubic symphysis. The anterior level II supports suspend the mid-portion of the anterior vaginal wall, creating the anterior lateral vaginal sulci. Detachment of these lateral supports can lead to paravaginal defects and prolapse of the anterior vaginal wall.

In addition to the anterior paravaginal supports, there are posterior lateral supports at level II as well. The posterior vaginal wall is attached laterally to the pelvic sidewall in a slightly more complex arrangement than the anterior vaginal wall. The distal half of the posterior vaginal wall fuses with the aponeurosis of the levator ani muscle from the perineal body along a line referred to as the arcus tendineus rectovagi-

nalis. It converges with the ATFP at a point approximately midway between the pubic symphysis and the ischial spine.<sup>23</sup> Along the proximal half of the vagina, the anterior and posterior vaginal walls are both supported laterally to the ATFP. Thus, in the proximal vagina, the lateral supports for the anterior and posterior vaginal wall are identical. This arrangement accounts for the H-shape or box-like configuration of the distal vagina when viewed in cross-section and the flattened-tube configuration seen in the upper vagina (Figure 7).

Level III support is provided by the perineal membrane, the muscles of the deep perineal space, and the perineal body. These structures support and maintain the normal anatomical position of the urethra and



the distal third of the vagina, which is perpendicular to the floor in a standing woman. At level III, the vagina fuses with the urethra anteriorly and with the perineal body posteriorly. Disruption of level III support anteriorly can result in urethral hypermobility and stress incontinence, and disruption posteriorly may result in distal rectoceles and/or perineal descent.

#### ■ INTERACTIONS BETWEEN MUSCULAR AND CONNECTIVE TISSUE SUPPORTS

Normal pelvic organ support and function depends on dynamic interaction between the pelvic floor musculature and the endopelvic fascia. In a standing woman, the endopelvic fascia suspends the upper vagina, the bladder, and the rectum over the levator plate while the pelvic floor muscles close the urogenital hiatus and provide a stable platform on which the pelvic viscera rests. Intra-abdominal and gravitational forces are applied perpendicular to the vagina and pelvic floor while the pelvic floor musculature counters those forces with its constant tone by closing. With proper tone of the pelvic floor muscles, stress on the connective tissue attachments is minimized. Furthermore, in times of acute stress, such as a cough or a sneeze, there is a reflex contraction of the pelvic floor musculature, countering and further stabilizing the viscera. The genital hiatus also responds by narrowing to maintain level III support.

With pelvic floor weakness, such as neuropathic injury or mechanical muscular damage, there is loss of the horizontal orientation of the levator plate, the urogenital hiatus opens, and the pelvic floor assumes a more bowl-like configuration. The endopelvic fascia then becomes the primary mechanism of support. Over time, this stress can overcome the endopelvic fascial attachments and result in loss of the normal anatomic position through breaks, stretching, or attenuation of these connective tissue supports. This can result in changes in the vector forces applied to the viscera and may lead to pelvic organ prolapse and/or dysfunction.

#### ■ URETHRAL CONTINENCE MECHANISM

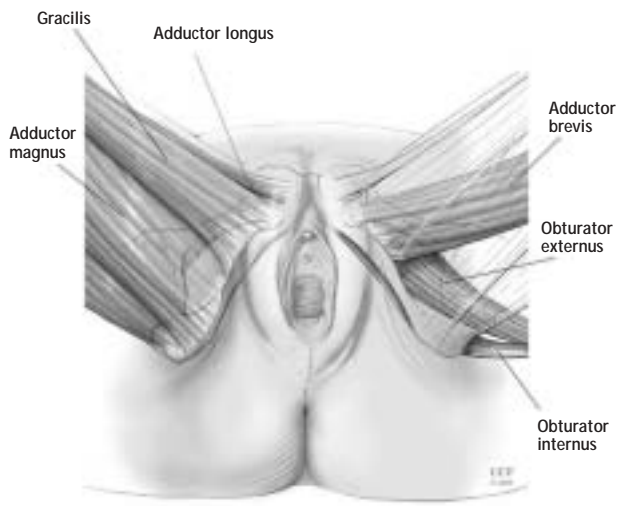
The urethra is about 3.5 to 4 cm long and averages 6 mm in diameter. Its lumen is slightly curved as it passes from the retropubic space, perforates the perineal membrane, and ends with its external orifice in the vestibule directly above the vaginal opening. Throughout most of its length, the urethra is fused to the anterior vaginal wall.

Histologically, the urethra has four distinct layers: mucosa, submucosa, internal urethral sphincter

(smooth muscle), and striated external urethral sphincter. The submucosal layer is highly vascular. These vascular cushions, along with the urethral mucosa, account for approximately one third of the urethral resting tone, while the internal and external urethral sphincters account for the remainder.<sup>24</sup> The internal urethral sphincter is composed primarily of oblique and longitudinal smooth muscle fibers, with a few circularly oriented outer fibers. The precise function of this longitudinal smooth muscle is not known, but Schafer makes a strong argument on biomechanical grounds that these longitudinal fibers serve as “filler volume” within the circular smooth muscle and striated urethral sphincter and that their presence improves the efficiency of the sphincter mechanism by allowing closure of the urethral lumen with only a small amount of circular muscle shortening.<sup>25</sup>

The skeletal muscle component of the urethral sphincter consists of the external urethral sphincter (also called sphincter urethrae) along with the previously described compressor urethrae and urethrovaginalis muscles. These three muscles, which function as a single unit, have been called by Oelrich the *striated urogenital sphincter*.<sup>17</sup> Together, they are approximately 2.5 cm long and encircle the urethra in its mid-portion from just below the bladder neck to the perineal membrane within the deep perineal space. The striated urogenital sphincter provides approximately one third of urethral resting tone and is responsible for the voluntary and reflex increases in intraurethral pressure needed to maintain continence.

Normal urethral function depends upon normal support of the urethra as well as its intrinsic sphincter mechanism. As with vaginal support, dynamic interaction between the levator ani muscle complex and the connective tissue supports of the urethra is essential. The urethra lies on a hammock-like supportive layer composed of periurethral endopelvic fascia and anterior vaginal wall.<sup>26</sup> Increased intra-abdominal pressure, as with a cough or sneeze, causes compression of the urethra against this hammock-like layer, thereby compressing the urethral lumen closed. The stability of the suburethral layer depends on the intact connection of the anterior vaginal wall and its connective tissue attachments to the ATRP and levator ani muscles. These attachments allow the pelvic floor muscle's normal resting tone to maintain the position of the urethra and bladder neck. They are also responsible for the posterior movement of the vesical neck seen at the onset of micturition (when the pelvic floor relaxes) and for the elevation noted when a patient is instructed to arrest her urinary stream.



**FIGURE 8.** Muscles of the obturator compartment. The superficial muscles are illustrated on the left. On the right, the superficial muscles have been made transparent to allow depiction of the deeper muscles.

Defects in these attachments can result in proximal urethral support defects (urethral hypermobility) or anterior vaginal wall prolapse (cystocele), and can contribute to stress urinary incontinence.

### ■ OBTURATOR ANATOMY

The obturator *membrane* is a fibrous sheath that spans the obturator *foramen* through which the obturator neurovascular bundle penetrates via the obturator *canal*. The obturator internus muscle lies on the superior (intrapelvic) side of the obturator membrane. The origin of the obturator internus is on the inferior margin of the superior pubic ramus and the pelvic surface of the obturator membrane. Its tendon passes

### ■ REFERENCES

1. Mattox TF, Lucente V, McIntyre P, Miklos JR, Tomezko J. Abnormal spinal curvature and its relationship to pelvic organ prolapse. *Am J Obstet Gynecol* 2000; 183:1381–1384.
2. Nguyen JK, Lind LR, Choe JY, McKindsey F, Sinow R, Bhatia NN. Lumbosacral spine and pelvic inlet changes associated with pelvic organ prolapse. *Obstet Gynecol* 2000; 95:332–336.
3. Sze EH, Kohli N, Miklos JR, Roat T, Karram MM. Computed tomography comparison of bony pelvic dimensions between women with and without genital prolapse. *Obstet Gynecol* 1999; 93:229–232.
4. Handa VL, Pannu HK, Siddique S, Gutman R, VanRooyen J, Cundiff G. Architectural differences in the bony pelvis of women with and without pelvic floor disorders. *Obstet Gynecol* 2003; 102:1283–1290.
5. Kearney R, Sawhney R, DeLancey JOL. Levator ani muscle anatomy evaluated by origin-insertion pairs. *Obstet Gynecol* 2004; 104:168–173.
6. Lawson JO. Pelvic anatomy. I. Pelvic floor muscles. *Ann R Coll Surg Engl* 1974; 52:244–252.

through the lesser sciatic foramen to insert onto the greater trochanter of the femur to laterally rotate the thigh. The obturator artery and vein originate as branches of the internal iliac vessels. As they emerge from the cranial side of the obturator membrane via the obturator canal and enter the obturator space, they divide into many small branches supplying the muscles of the adductor compartment of the thigh.

Recent cadaver work by Whiteside and Walters has contradicted previous reports that the obturator vessels bifurcate into medial and lateral branches.<sup>27</sup> Rather, the vessels are predominantly small (<5 mm in diameter) and splinter into variable courses. The muscles of the medial thigh and adductor compartment are (from superficial to deep): the gracilis, adductor longus, adductor brevis, adductor magnus, obturator externus, and obturator internus (**Figure 8**).

In contrast to the vessels, the obturator nerve emerges from the obturator membrane and bifurcates into anterior and posterior divisions traveling distally down the thigh to supply the muscles of the adductor compartment. With the patient in the dorsal lithotomy position, the nerves and vessels follow the thigh and course laterally away from the ischiopubic ramus.

### ■ CONCLUSIONS

Although human anatomy is unchanging, our understanding of the functional anatomy of the pelvic viscera and the biomechanics of pelvic organ support continues to evolve. Familiarity with the contemporary views of female pelvic organ support is essential as we refine established methods for surgically correcting pelvic organ prolapse or consider adopting new and innovative technologies. The fundamentals reviewed in this article should serve as a useful foundation for the practicing pelvic reconstructive surgeon.

7. Singh K, Jakab M, Reid WM, Beyer LA, Hoyte L. Three-dimensional assessment of levator ani morphologic features in different grades of prolapse. *Am J Obstet Gynecol* 2003; 188:910–915.
8. DeLancey JOL, Kearney R, Chou Q, Speights S, Binu S. The appearance of levator ani muscle abnormalities in magnetic resonance imaging after vaginal delivery. *Obstet Gynecol* 2003; 101:46–53.
9. Barber MD, Bremer RE, Thor KB, Dolber PC, Kuehl TJ, Coates KW. Innervation of the female levator ani muscles. *Am J Obstet Gynecol* 2002; 187:64–71.
10. Snooks SJ, Swash M. The innervation of the muscles of continence. *Ann R Coll Surg Engl* 1986; 68:45–49.
11. Percy JP, Neill ME, Swash M, Parks AG. Electrophysiological study of motor nerve supply of pelvic floor. *Lancet* 1981; 1:16–17.
12. Pierce LM, Reyes M, Thor KB, et al. Innervation of the levator ani muscles in the female squirrel monkey. *Am J Obstet Gynecol* 2003; 188:1141–1147.
13. Bremer RE, Barber MD, Coates KW, Dolber PE, Thor KB. Innervation of the levator ani and coccygeus muscles of the female rat. *Anat Rec* 2003; 275:1031–1041.



14. **Vanderhorst VG, Holstege G.** Organization of lumbosacral motoneuronal cell groups innervating hindlimb, pelvic floor, and axial muscles in the cat. *J Comp Neurol* 1997; 382:46–76.
15. **Mirilas P, Skandalakis JE.** Urogenital diaphragm: an erroneous concept casting its shadow over the sphincter urethrae and deep perineal space. *J Am Coll Surg* 2003; 198:279–289.
16. **DeLancey JOL.** Structural anatomy of the posterior pelvic compartment as it relates to rectocele. *Am J Obstet Gynecol* 1999; 180:815–823.
17. **Oelrich TM.** The striated urogenital sphincter muscle in the female. *Anat Rec* 1983; 205:223–232.
18. **Funt MI, Thompson JD, Birch H.** Normal vaginal axis. *South Med J* 1978; 71:1534–1535.
19. **Weber AM, Walters MD.** Anterior vaginal prolapse: review of anatomy and techniques of surgical repair. *Obstet Gynecol* 1997; 89:331–338.
20. **Boreham MK, Wai CY, Miller RT, Schaffer JI, Word RA.** Morphometric analysis of smooth muscle in the anterior vaginal wall of women with pelvic organ prolapse. *Am J Obstet Gynecol* 2002; 187:56–73.
21. **DeLancey JOL.** Anatomic aspects of vaginal eversion after hysterectomy. *Am J Obstet Gynecol* 1992; 166:17–28.
22. **Umek WH, Morgan DM, Ashton-Miller JA, DeLancey JOL.** Quantitative analysis of uterosacral ligament origin and insertion points by magnetic resonance imaging. *Obstet Gynecol* 2004; 103:447–451.
23. **Leffler KS, Thompson JR, Cundiff GW, Buller JL, Burrows LJ, Schön Ybarra MA.** Attachment of the rectovaginal septum to the pelvic sidewall. *Am J Obstet Gynecol* 2001; 185:41–43.
24. **Bump RC, Friedman CI, Copeland WE.** Non-neuromuscular determinants of intraluminal urethral pressure in the female baboon: relative importance of vascular and nonvascular factors. *J Urol* 1988; 139:162–164.
25. **Schafer W.** Some biomechanical aspects of continence function. *Scand J Urol Nephrol Suppl* 2001; 207:44–60.
26. **DeLancey JO.** Structural support of the urethra as it relates to stress urinary incontinence: the hammock hypothesis. *Am J Obstet Gynecol* 1994; 170:1713–1723.
27. **Whiteside JL, Walters MD.** Anatomy of the obturator region: relations to a transobturator sling. *Int Urogynecol J* 2004; 15:223–226.